

Oral Tube placement in a premature infant

Jacob Dangerfield

November 22, 2019

Diagnostic Radiology. Rad 4001

Dr. Katrina S. Hughes MD

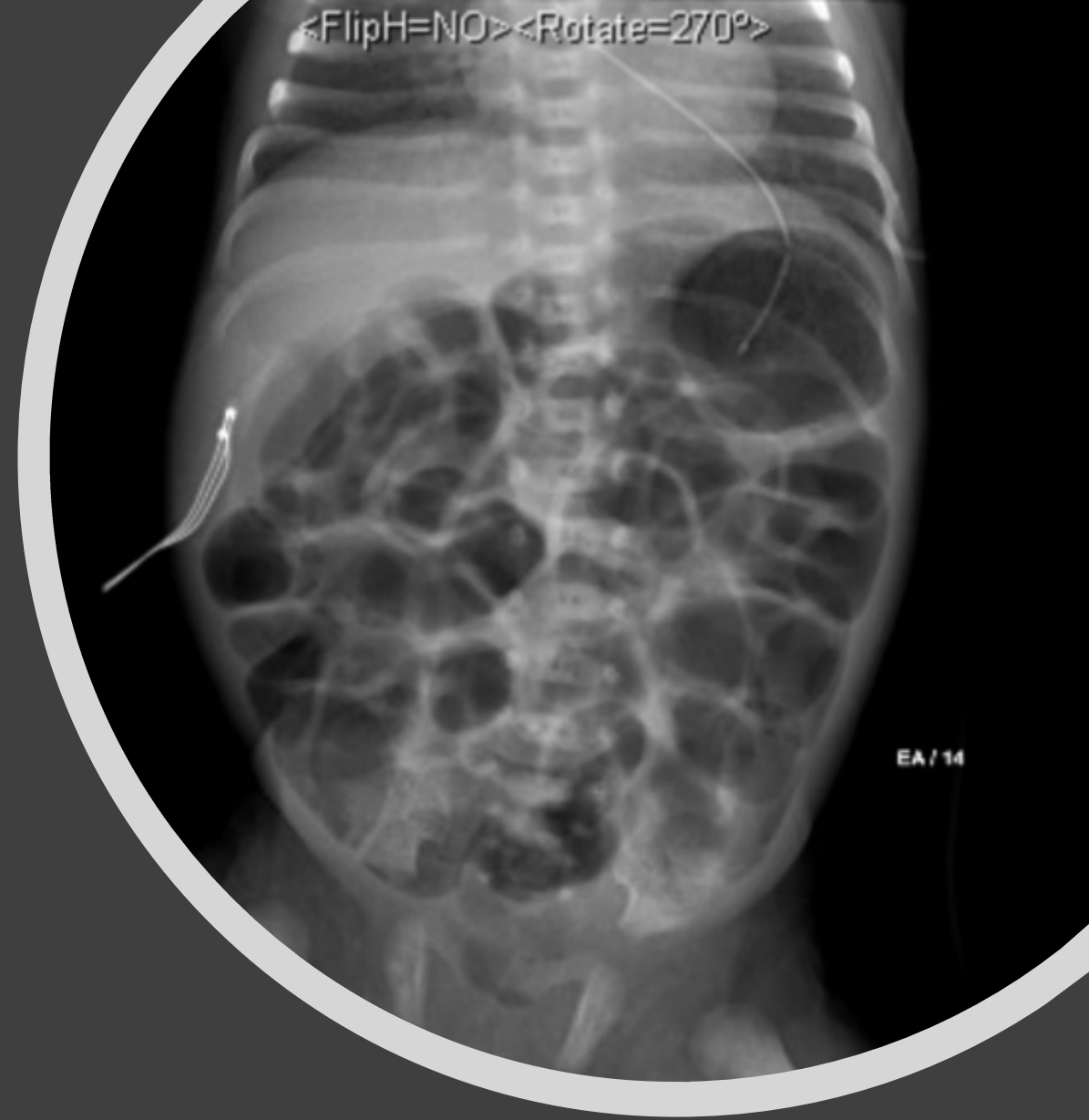

Clinical History

- History and Physical Exam
 - 11 day old premature male. Born at 31 weeks.
 - Receiving an OG tube for nutrition and growth.
 - History also significant for respiratory distress.
 - OG Tube is placed and feeds are started. Shortly afterward patient begins to have respiratory distress, blood in the OG tube, and there is concern for aspiration. Chest/ABD radiogram is taken.

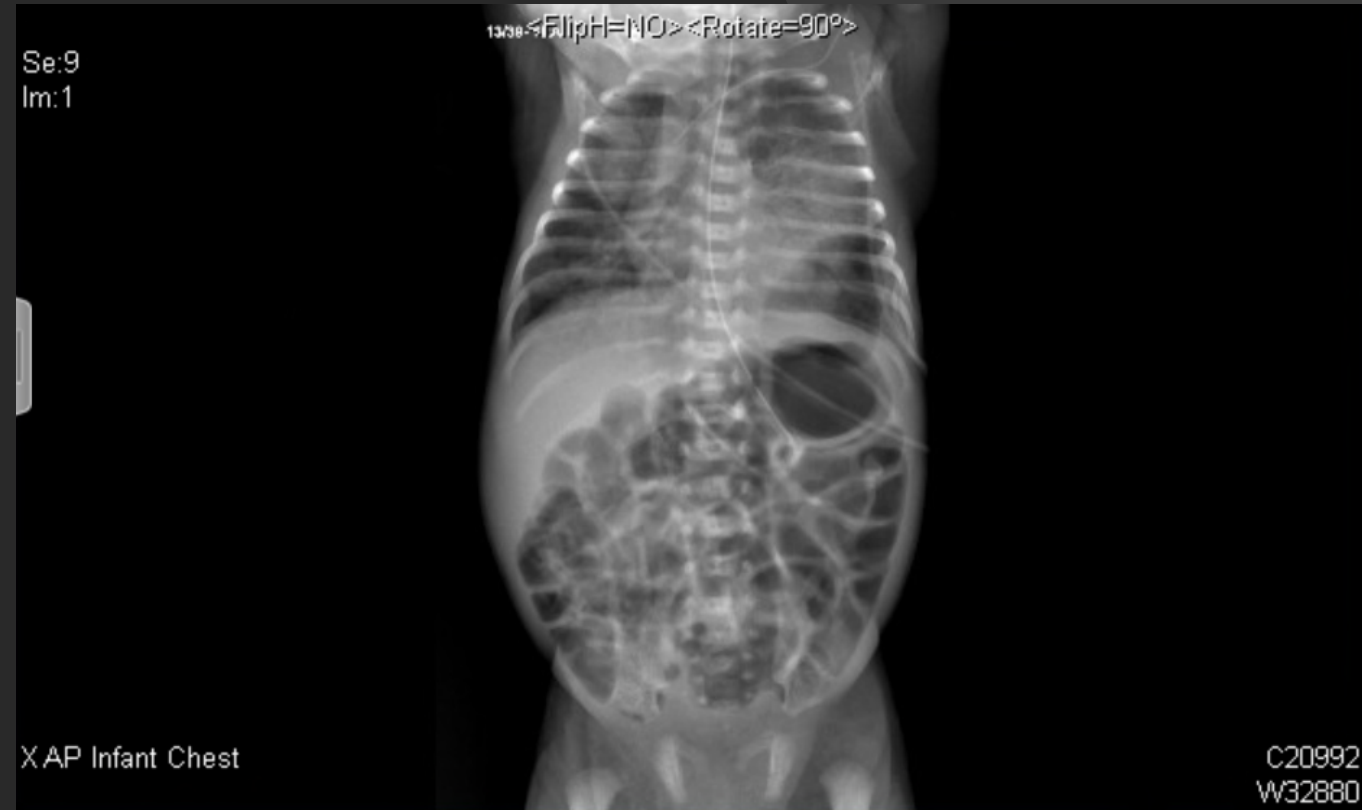Relevant Imaging

- Pedigogram taken to assess for placement of tube.
- Scan shows that the enteric tube takes an unusual course
 - This is concerning for intrathoracic placement
 - Advised to replace the tube and continue interval follow up.

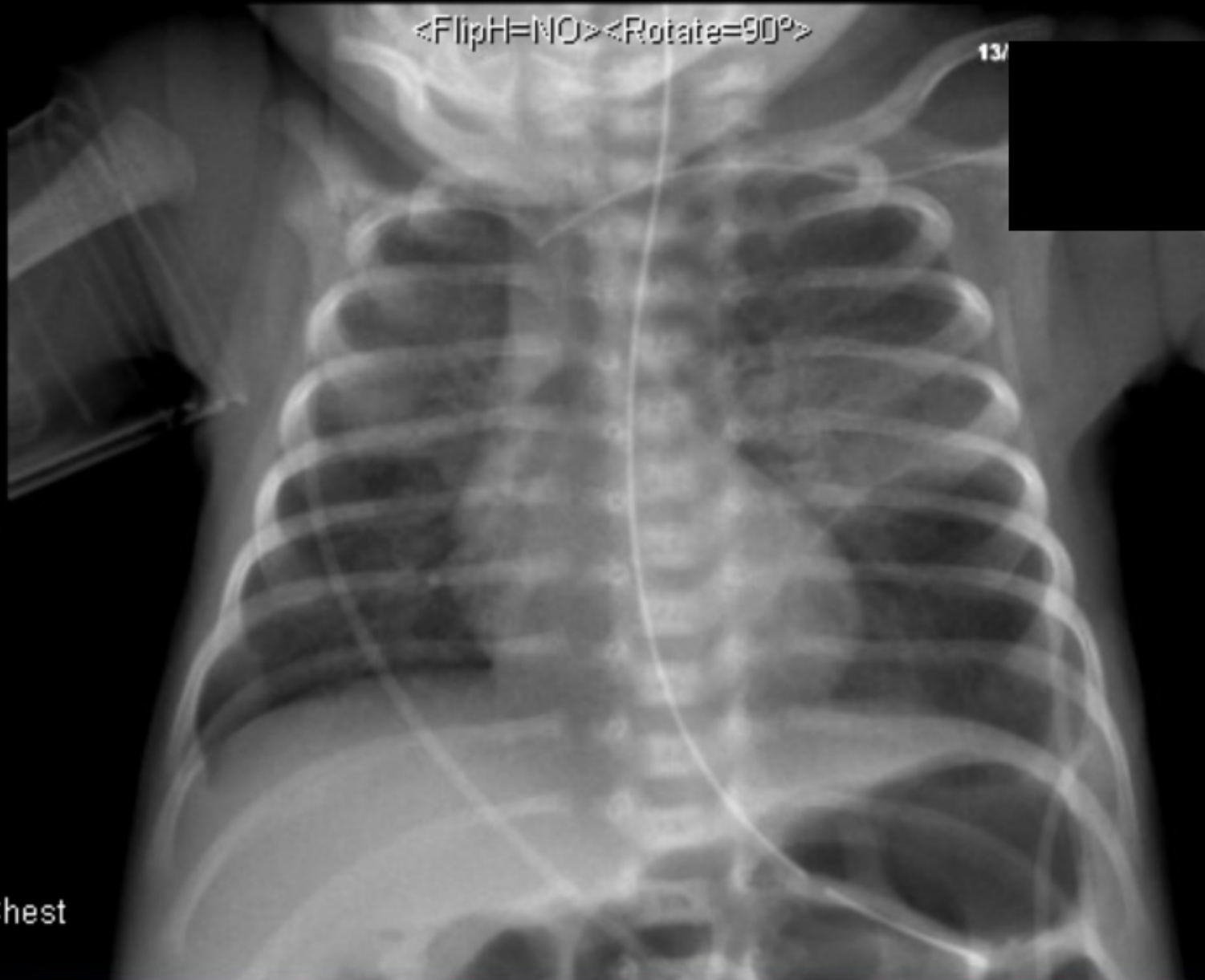


Tube is removed and replaced and another pediogram is taken

- Here the tip of the tube is in the expected location in the stomach.
- A new, rounded lucency is seen at the left lower chest, as well as some left mid lung and right upper lobe opacities. .



Se:11
Im:1



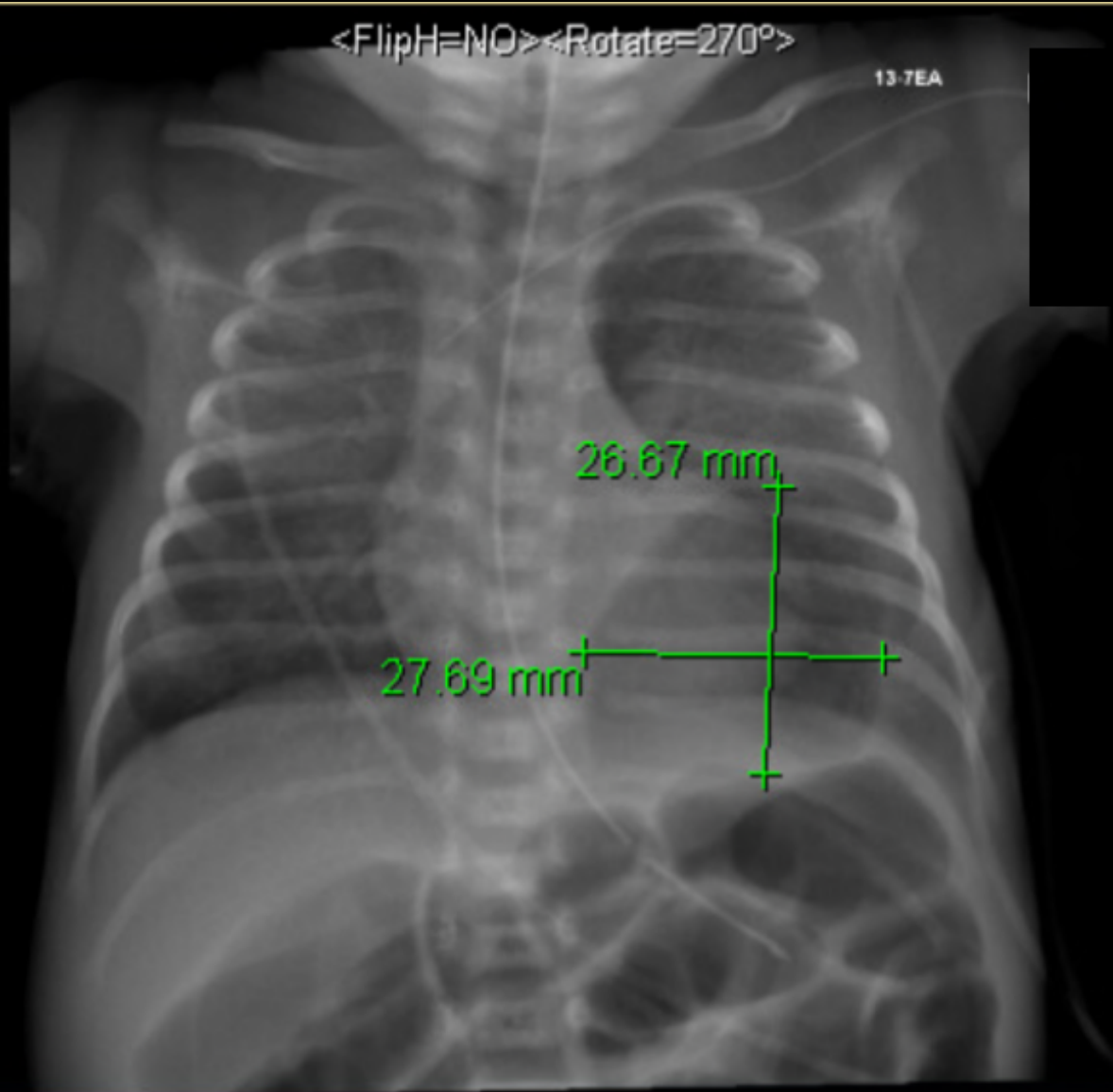
XAP Infant Chest

C22098
W34443

Se:10
Im:1

<FlipH=NO><Rotate=270°>

13-7EA



X AP Infant Chest

C28437
W51650

Differential Diagnosis

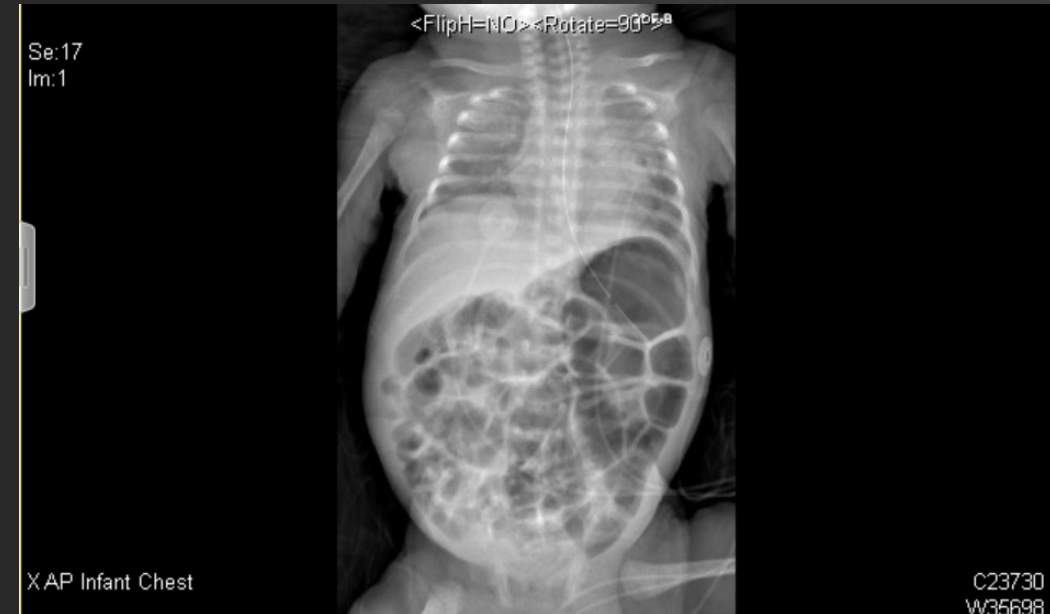- Pneumothorax
- Pneumatocele
- Aspiration Pneumonia

Discussion

- A pneumatocele is a thin walled, air filled cyst within the lung parenchyma. A pneumothorax often occurs as a sequelae of a ruptured pneumatocele. A pneumatocele is prone to spontaneous resolution.
- Given the patient's respiratory distress, and the finding of a possibly misplaced tube, the likely diagnosis is a left pneumatocele, along with some left mid lung atelectasis. We suspect this over a pneumothorax given the shape of the air filled space and its growing nature. The patient has remained afebrile indicating that aspiration pneumonia is less likely to be the diagnosis.
- Close follow up is needed in this situation. Along with this follow up, it is important that the patient's respiratory status is watched closely to insure that they are not having desaturations or tachypnea. The pneumatocele should spontaneously resolve over time.

Final Diagnosis

- A left lung pneumatocele.
- Two weeks later a Chest/ ABD Pedigogram was taken showing that the left lung opacity began to spontaneously resolve. Due to this, the final diagnosis is a left lung pneumatocele vs a loculated pneumothorax.



ACR appropriateness Criteria

- According to the ACR guidelines, it is highly appropriate to take a portable chest x-ray after placement of a oral tube and/or catheter.
- Each chest x-ray costs \$683 at Memorial Hermann Hospital. This patient received 3 X-rays on the day of tube placement.
 - The cost to an insured patient: \$250 per chest x-ray.
 - To uninsured: \$246 per CXR.

Variant 4: Post-insertion of tube or catheter.			
Radiologic Procedure	Rating	Comments	RRL*
X-ray chest portable	9		⊕
Rating Scale: 1,2,3 Usually not appropriate; 4,5,6 May be appropriate; 7,8,9 Usually appropriate			*Relative Radiation Level

Recommendation

Based on limited evidence, small-bore feeding tubes may, in a small but significant number of patients, be inadvertently placed in the bronchi or lungs. This error is not always detected clinically and may lead to injection of feeding material into the lung or tube penetration of the pleura, with subsequent pneumothorax. A chest radiograph is warranted after initial nasogastric tube insertion and before the first feeding. Beyond the initial chest radiograph, follow-up chest radiographs are not required for managing stable tubes.

Take Home Points

- Before initiating use of any type of line, first confirm that it has been correctly placed.
- With an NG/OG tube, take a KUB to confirm placement in the stomach.
- If there are any doubts regarding correct placement of an OG tube, **IMMEDIATELY** turn off feeds and discover cause of problems before restarting.

References

- Care4, Centricity, and Dr. Katrina Hughes.
- <https://www.memorialhermann.org/patients-caregivers/pricing-estimates-and-information/>
- <https://acsearch.acr.org/docs/69452/Narrative/>
- <https://www.sciencedirect.com/topics/medicine-and-dentistry/pneumatocele>



Questions?