

# Ruptured Ectopic Pregnancy

Tammy Trinh

January 5, 2020

Diagnostic Radiology, RAD 4001

Dr. Matthew Bledsoe



# Clinical History

- 30 yo female with no PMH, presents to ED with sharp abdominal pain + vaginal bleeding. 6 weeks pregnant.
  - Was seen at OSH around Christmas and went to ED for vaginal spotting and elevated HCG with no IUP and was told to follow up.
  - Sharp abdominal pain began last night. Tylenol with no relief. Denies fevers, chills, N/V.

# Vitals

ER Triage vitals:

- Temp 98.3F
- **HR 113**
- BP 100/63
- RR 99
- SpO2 99%

Patient is deemed stable.

# Physical Exam

Gen: Alert, NAD

CV: Regular rate and rhythm

Resp: CTAB

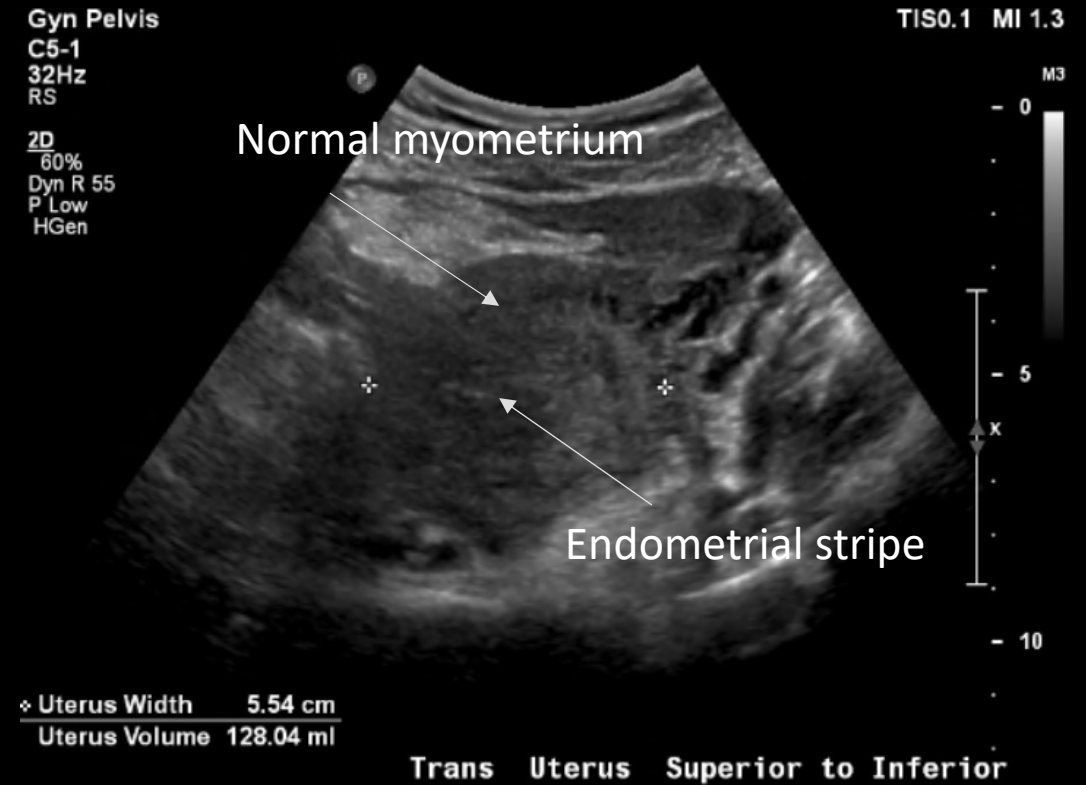
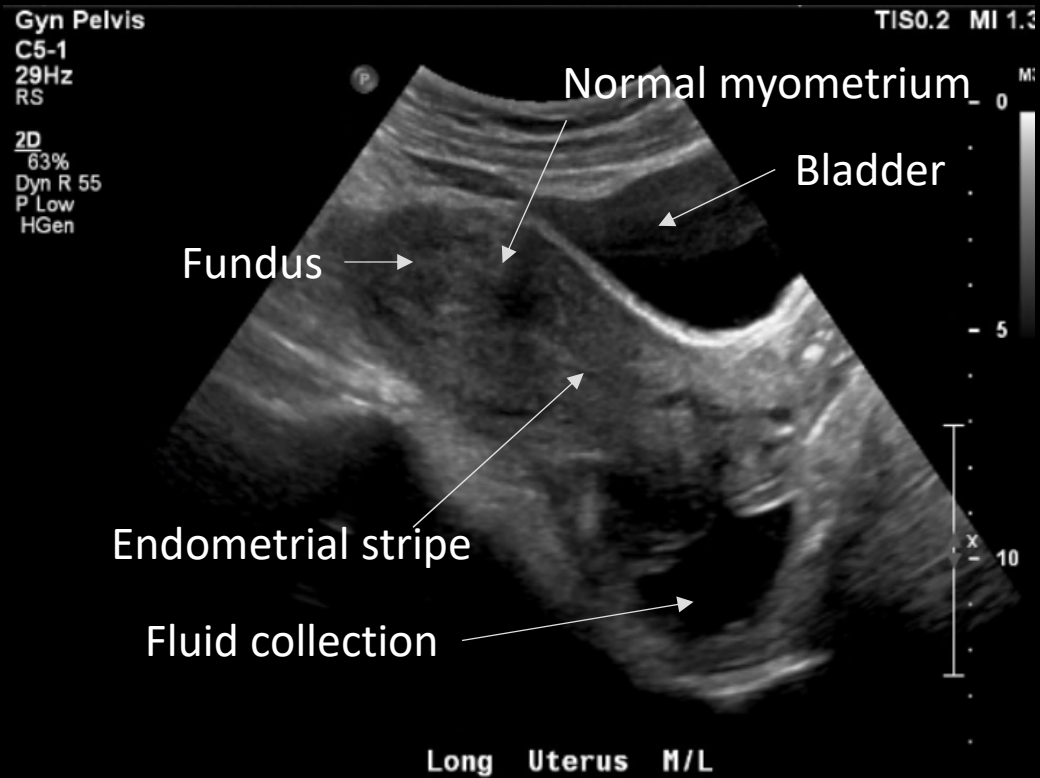
GI: soft, diffusely tender to exam mostly to the suprapubic and RUQ

GU: No external lesions, mild bleeding from cervix. Os is closed. No adnexal masses or tenderness elicited.

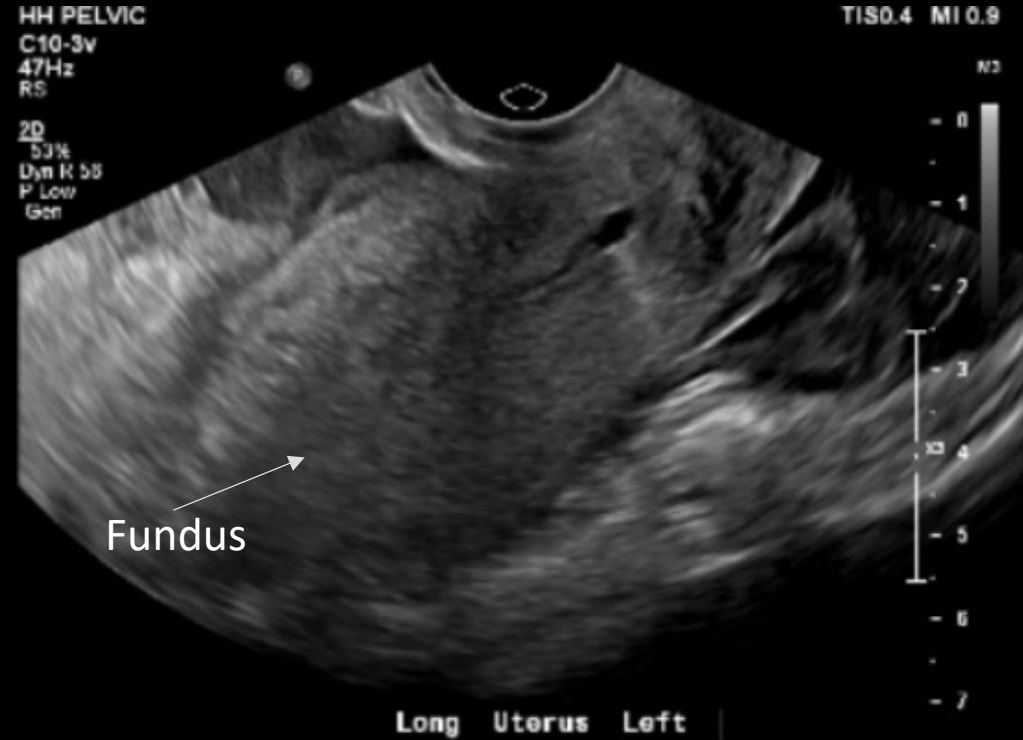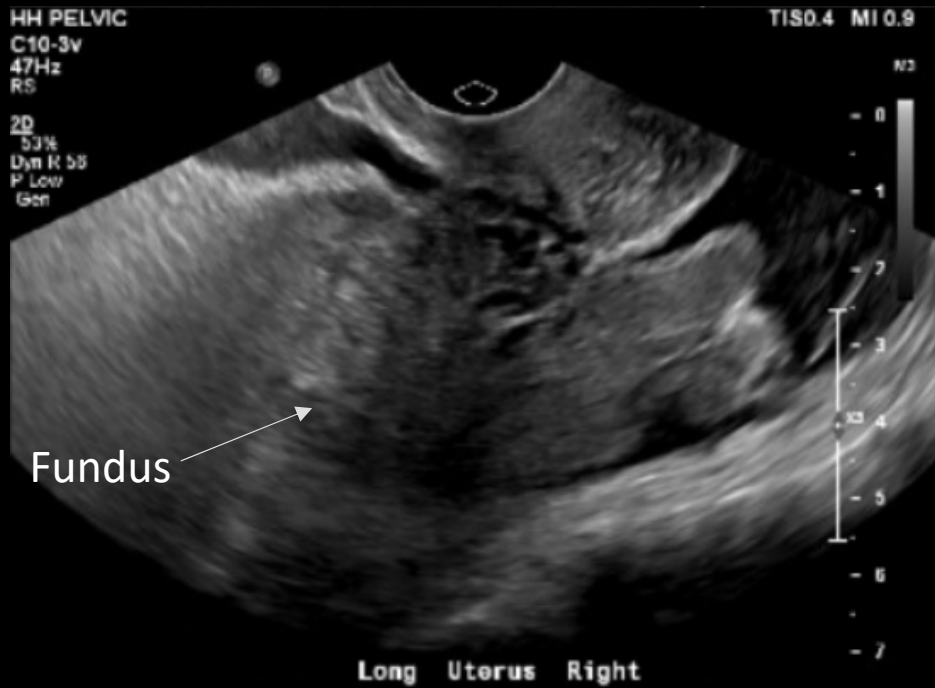# Initial Management

- B-hCG 31052
- H/H 10.2/29.9
- FAST exam performed
  - Sonographic views: Morrison's pouch, retrovesical, no free fluid seen to the abdomen or pelvis.
- Pelvis US Transvaginal/transabdominal w/ Doppler ordered

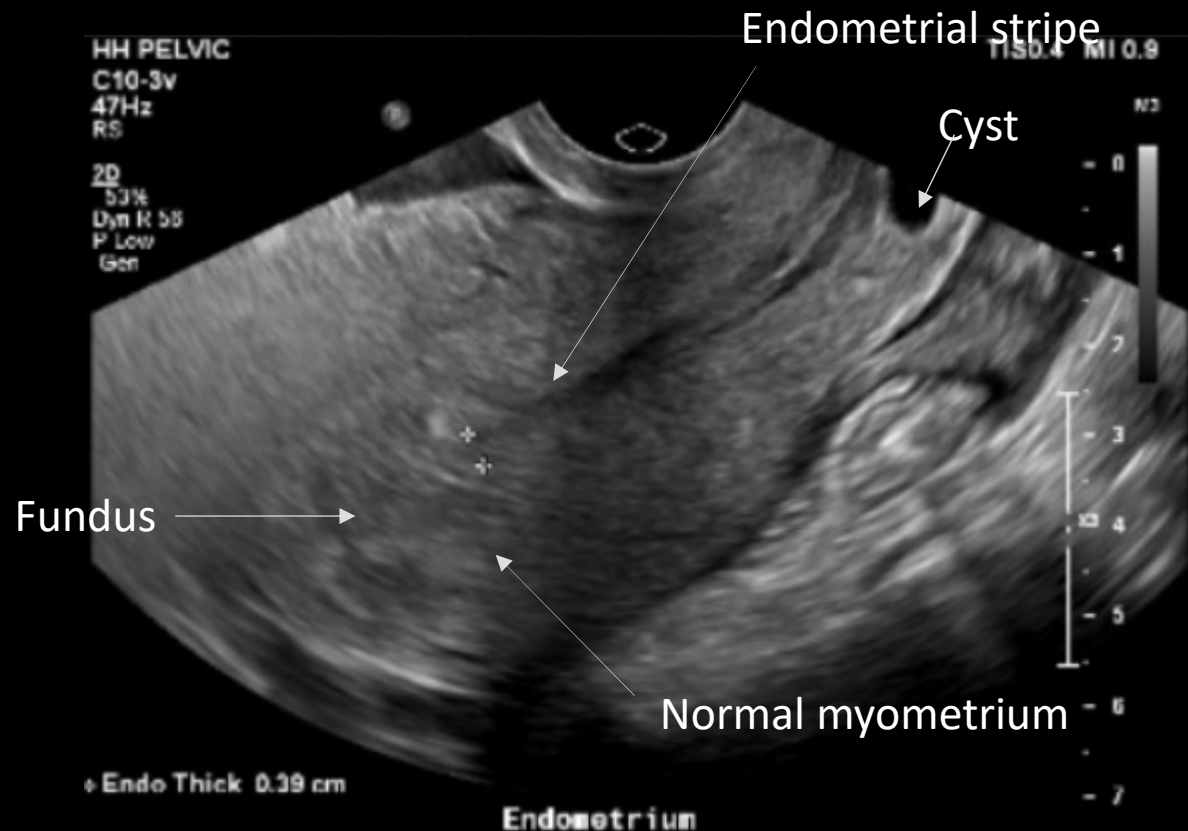
# Uterus – Transabdominal US



# Uterus – Transvaginal US



# Endometrium



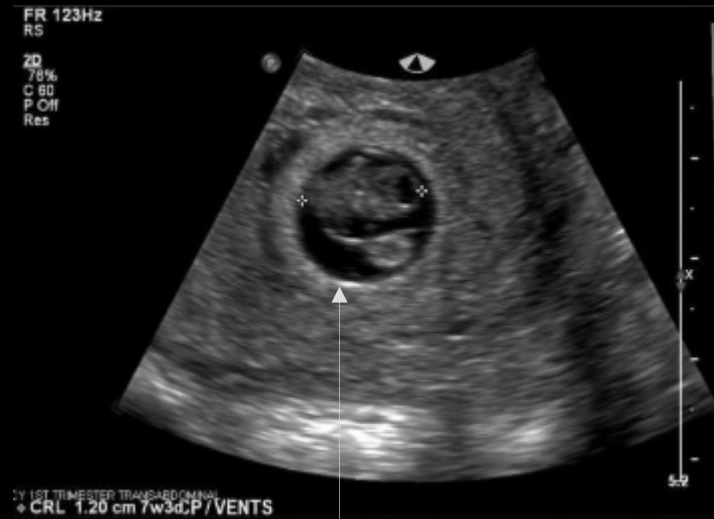Research shows that endometrial thickness can be a useful predictor for normal IUP in the setting of vaginal bleeding in pregnancy of unknown location.

No IUP had an endometrial thickness <8mm.

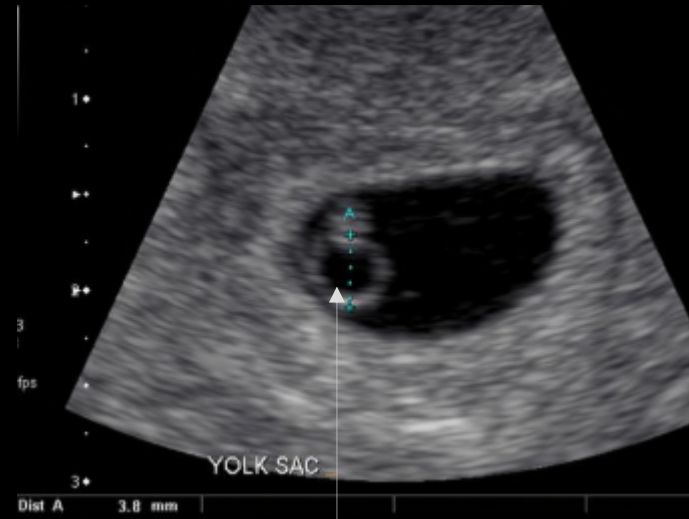
Our patient had an endometrial thickness of 0.39mm.



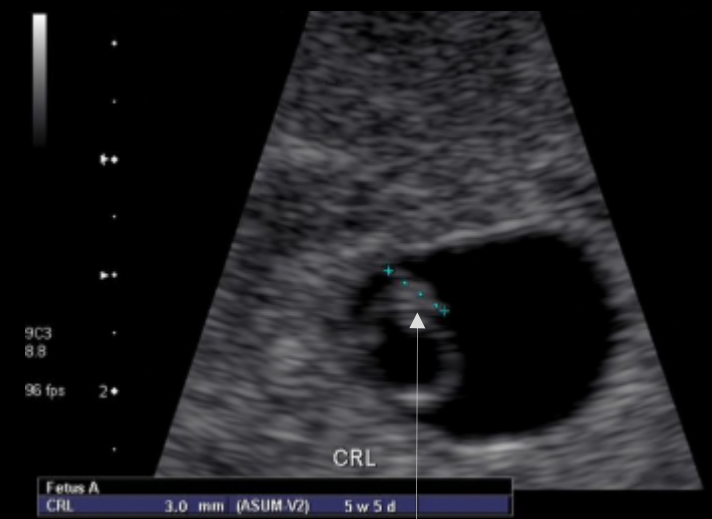# Ultrasound findings in early pregnancy



Gestational sac



Yolk sac



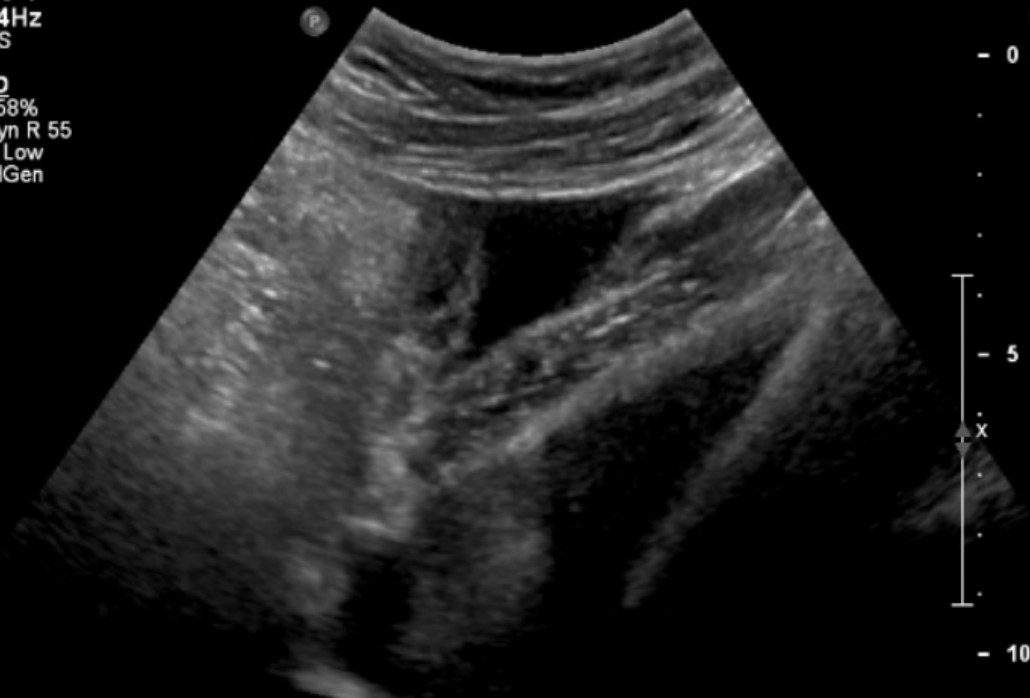Fetal pole

These are images from a transvaginal ultrasound

# Right adnexa

Gyn Pelvis  
C5-1  
34Hz  
RS

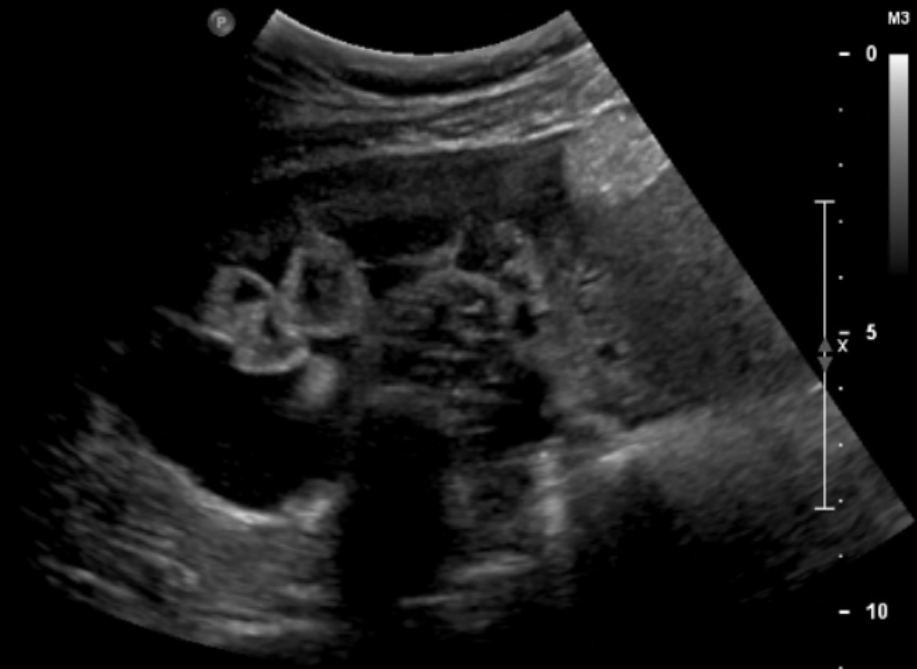2D  
58%  
Dyn R 55  
P Low  
HGen



Long Right Adnexa |

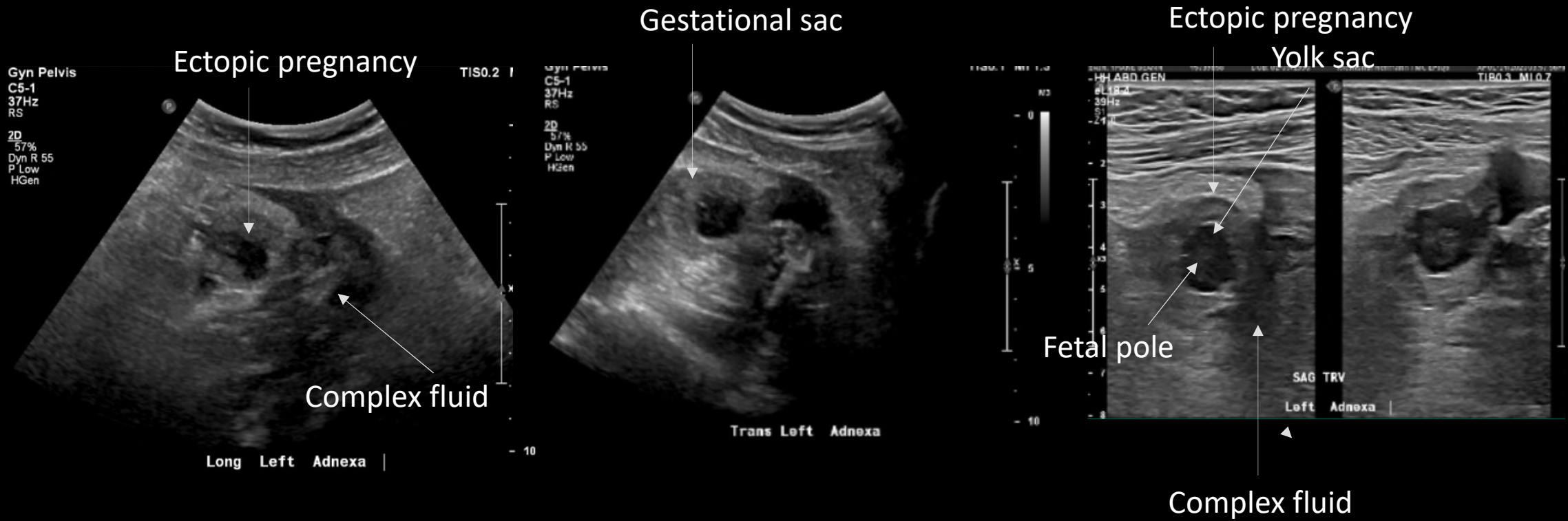Gyn Pelvis  
C5-1  
34Hz  
RS

2D  
58%  
Dyn R 55  
P Low  
HGen



Trans Right Adnexa

# Left Adnexa



# Differential Diagnosis

- **Ruptured ectopic pregnancy**
- Ruptured corpus luteum cyst
  - Identical radiological appearance as ruptured ectopic pregnancy except negative beta hCG
- Pregnancy of unknown location
  - Very early pregnancy – not yet detected w/ US
  - Completed abortion
  - Unidentified ectopic pregnancy
  - Nonviable intrauterine pregnancy not detected w/ US

# Discussion

- In this case, the patient had an elevated B-hCG of 31,052, presented with abdominal pain and vaginal bleeding, and confirmed US findings of left ectopic pregnancy, no IUP.
  - Patient's risk factors: h/o of chlamydia
- Clinical picture matches diagnosis of ruptured ectopic pregnancy!

Final Diagnosis

**Ruptured ectopic pregnancy**

# Discussion

- Pathophysiology of ruptured ectopic pregnancy
  - Ectopic pregnancy – implantation occurs in a site other than the endometrial lining of uterine cavity (fallopian tube, uterine cornua, cervix, ovary, abdominal/pelvic cavity)
  - Cannot be carried to term – eventually rupture (at 6-16wks) or involute
  - Early symptoms/signs = pelvic pain, vaginal bleeding, cervical motion tenderness
  - Syncope or hemorrhagic shock can occur with rupture
- Diagnosis = measurement of B-hCG and US
- Treatment = laparoscopic/open surgical resection w/ salpingectomy

# Continued discussion

- Surgical management is the gold standard
- In select patients who are hemodynamically stable w/ US evidence of no ongoing bleeding, expectant management (NPO, close observation of vitals, Hgb, sx of ongoing bleeding, IV fluids, tranexamic acid to prevent bleeding).
- If the ectopic pregnancy is small and unruptured, **methotrexate** may be given.



# Treatment

- For this patient: Diagnostic laparoscopy with excision of ectopic pregnancy and left salpingectomy
  - Findings: Left ectopic pregnancy near the interstitial area, 300 cc of hemoperitoneum
  - Patient tolerated the procedure well and was sent to PACU.
- No post-op or intervention imaging

# ACR appropriateness Criteria

- First trimester vaginal bleeding.
  - Both the US pelvis transvaginal and US pelvic transabdominal were **appropriate**.

American College of Radiology  
ACR Appropriateness Criteria®  
First Trimester Vaginal Bleeding

**Variant 1:** First trimester vaginal bleeding. Positive urine or serum pregnancy test.

Procedure	Appropriateness Category	Relative Radiation Level
US pelvis transvaginal	Usually Appropriate	0
US pelvis transabdominal	Usually Appropriate	0
US duplex Doppler uterus	May Be Appropriate	0
MRI pelvis without IV contrast	May Be Appropriate	0
MRI pelvis without and with IV contrast	Usually Not Appropriate	0
CT pelvis without IV contrast	Usually Not Appropriate	☼☼☼
CT pelvis with IV contrast	Usually Not Appropriate	☼☼☼
CT pelvis without and with IV contrast	Usually Not Appropriate	☼☼☼☼

# Cost at Memorial Herman

FAST exam \$215

U/S pelvis transabdominal \$1386

U/S pelvis transvaginal \$1136

**TOTAL (imaging): \$2737**

Avg. cost for ectopic pregnancy: \$28,682

# Case Summary

- 30 yo female, 6 weeks pregnant, presents with abdominal pain + vaginal bleeding
- Beta-hCG 31,052
- US transvaginal/transabdominal showed left ectopic pregnancy, hemoperitoneum
- Patient underwent diagnostic laparoscopy with excision of ectopic pregnancy and salpingectomy

# Take Home Points

- In first trimester patients presenting for vaginal bleeding +/- abdominal pain, US pelvic transvaginal and US pelvic transabdominal are the first steps in initial imaging.
- Ruptured ectopic pregnancy is considered a gynecologic emergency due to risk for hemorrhagic shock.
- Gold standard is surgery for excision of ectopic pregnancy.

# References

- <https://acsearch.acr.org/docs/69460/Narrative/>
- Dalsgaard Jensen T, Penninga L. Non-operative treatment of ruptured ectopic pregnancy. *BMJ Case Rep.* 2016;2016:bcr2016215311. Published 2016 Jun 13. doi:10.1136/bcr-2016-215311
- Moschos E, Twickler DM. Endometrial thickness predicts intrauterine pregnancy in with pregnancy of unknown location. *Ultrasound Obstet Gynecol.* 2008;32:929–34. doi: 10.1002/uog.6248.



Questions?