

Acute ACL Tear

Andy Wang

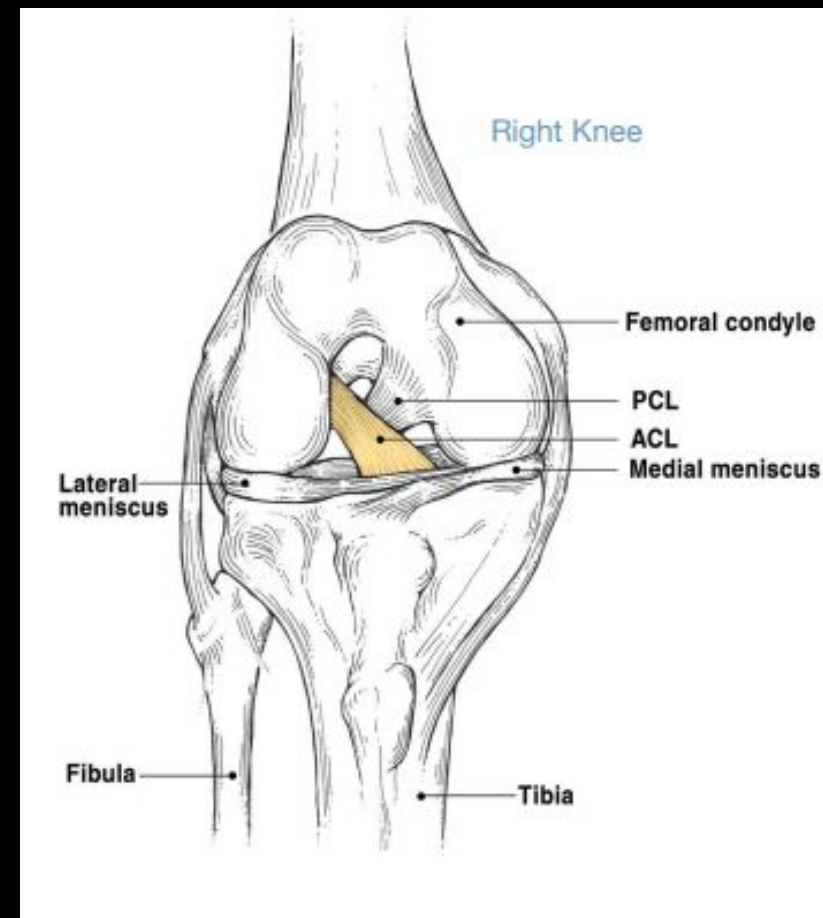
6/24

MSK Radiology: RAD4014

Dr. Manickam “Nicks” Kumaravel

ACL Anatomy

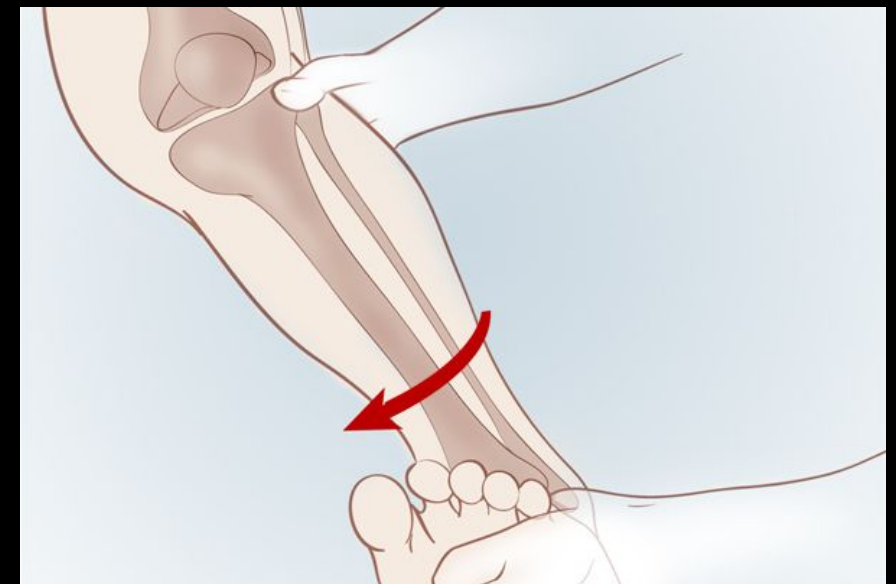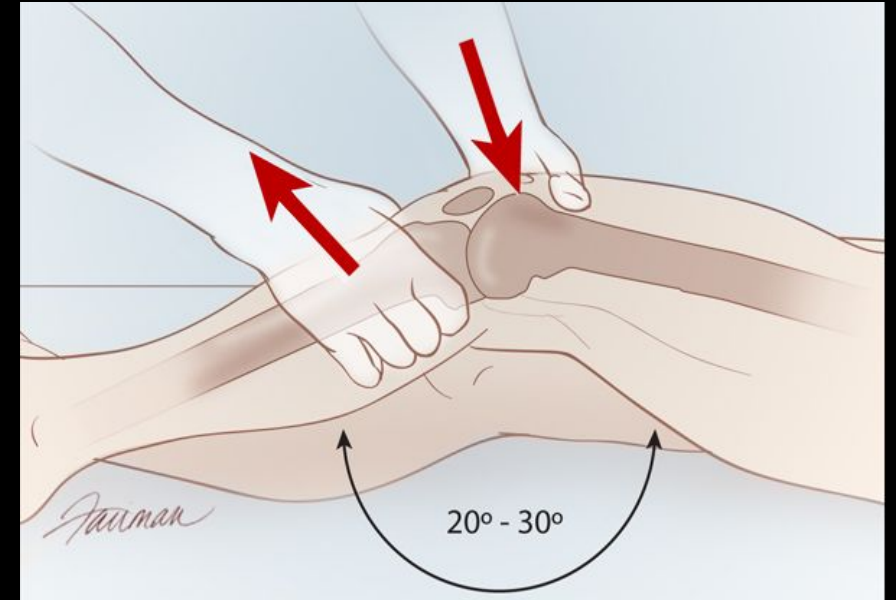
- Attaches at the posterior part of the inner surface of the lateral femoral condyle and runs anteriorly, medially, and distally to the tibia
- Broader and stronger at the tibial attachment
- The ACL can be split into two components: the anteromedial bundle (AMB) and the posterolateral bundle (PLB), with the PLB consisting of a greater proportion of fascicles than the AMB.



[https://www.ortho.wustl.edu/mm/files/ACL Tears Surgical Guide-Final.pdf](https://www.ortho.wustl.edu/mm/files/ACL%20Tears%20Surgical%20Guide-Final.pdf)

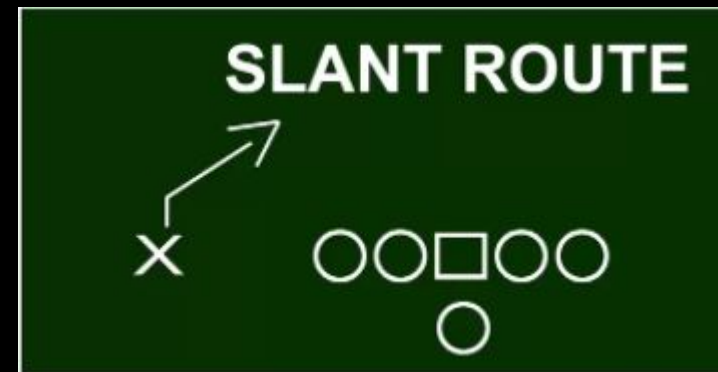
ACL Functionality

- Prevents anterior translation of the tibia from the femur.
- Restrain any rotation of the tibia on the femur during extension
- Tears of the ACL result in direct loss of these functions: leads to increased knee laxity and instability.
- Lachman test and Pivot-Shift test are used to assess for this loss of stability

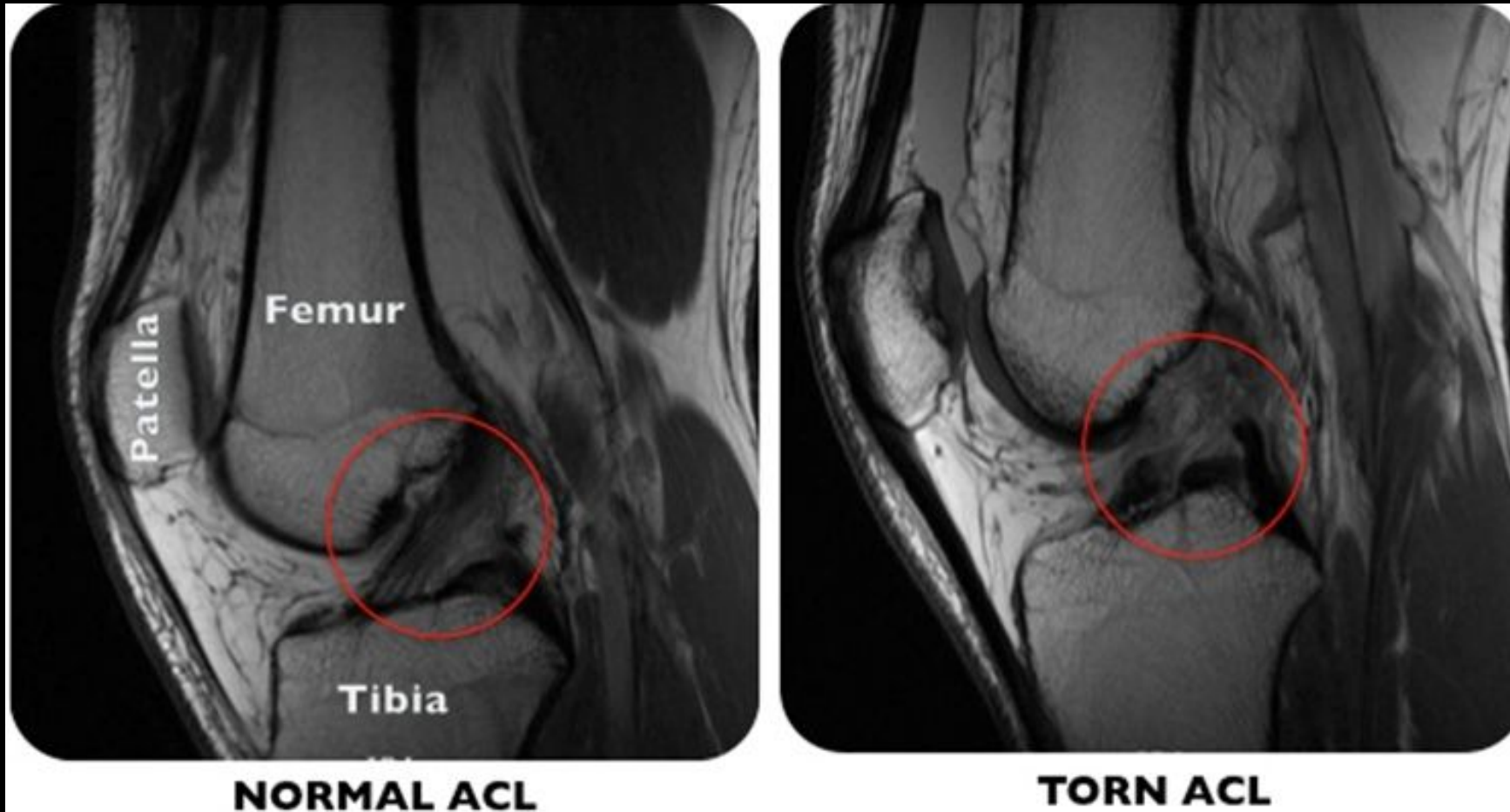


Clinical History

- 19 year old male with no past medical history presents with left knee pain and instability
- States he ran a slant route in football when he felt a pop and his left knee give away, he immediately felt pain and swelling
- On physical exam: 2+ effusion of the left knee, (+) anterior drawer test, guarding to pivot shift test, able to perform straight leg raise, neurovascular status is intact



Normal vs Tear



<https://health.ucsd.edu/specialties/surgery/ortho/knee/Pages/acl-tear.aspx#top>

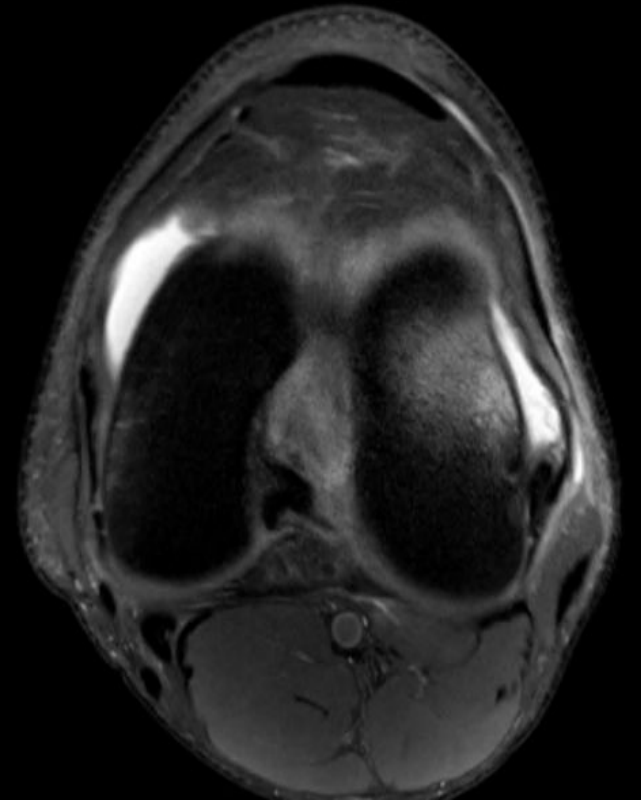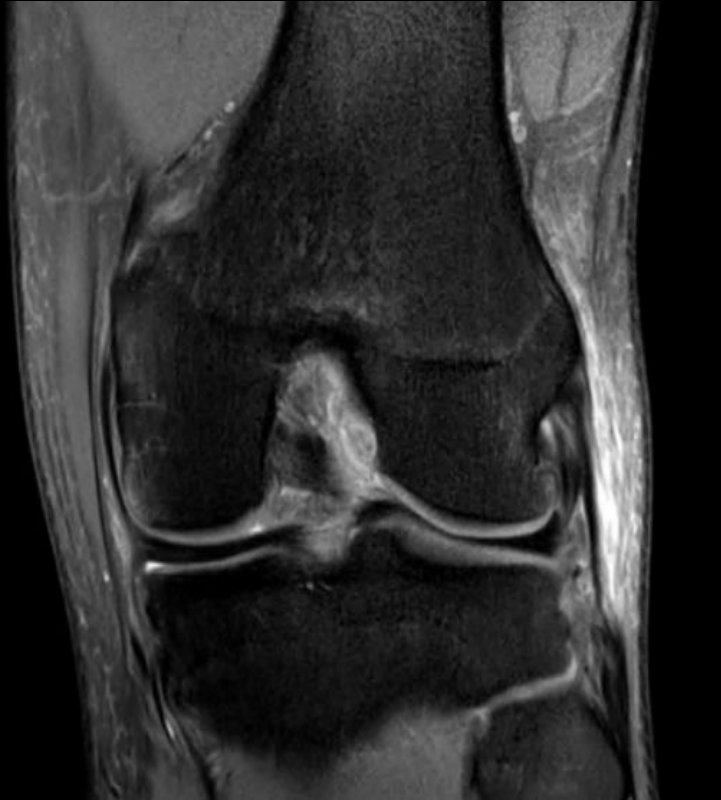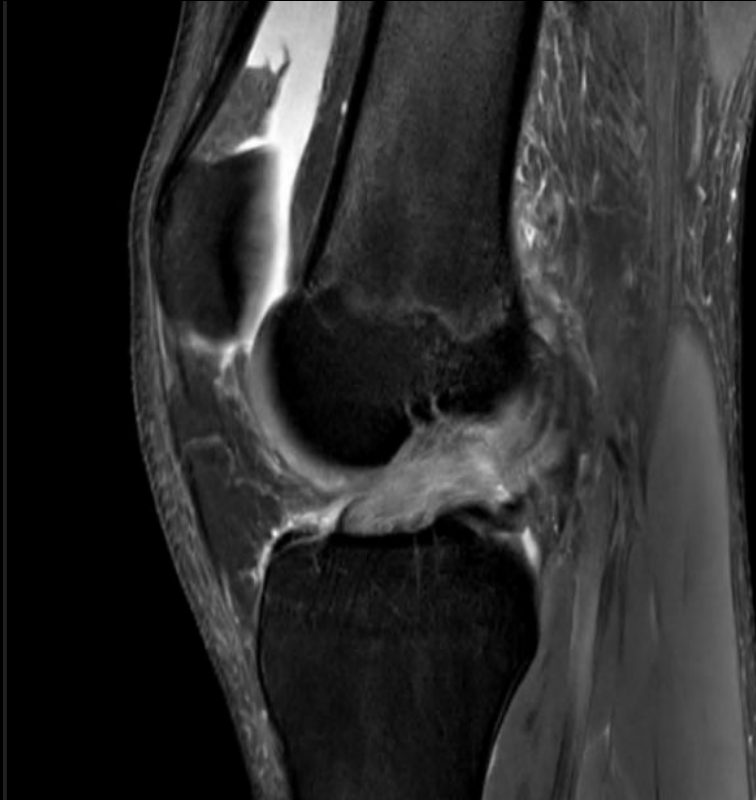Imaging Features

- Plain radiographs used to rule out fractures and dislocations
 - Indirect sign of tear include an avulsion fracture of the tibial/femoral insertion
- MRI provides the greatest utility
 - ACL usually shows consistent low to moderate signal intensity with continuous fibers throughout
 - Best seen in the oblique, sagittal view
- Direct sign of tear is discontinuation of the fibers
 - Accompanied by thickening and edema
 - Tears most commonly occur near the proximal insertion

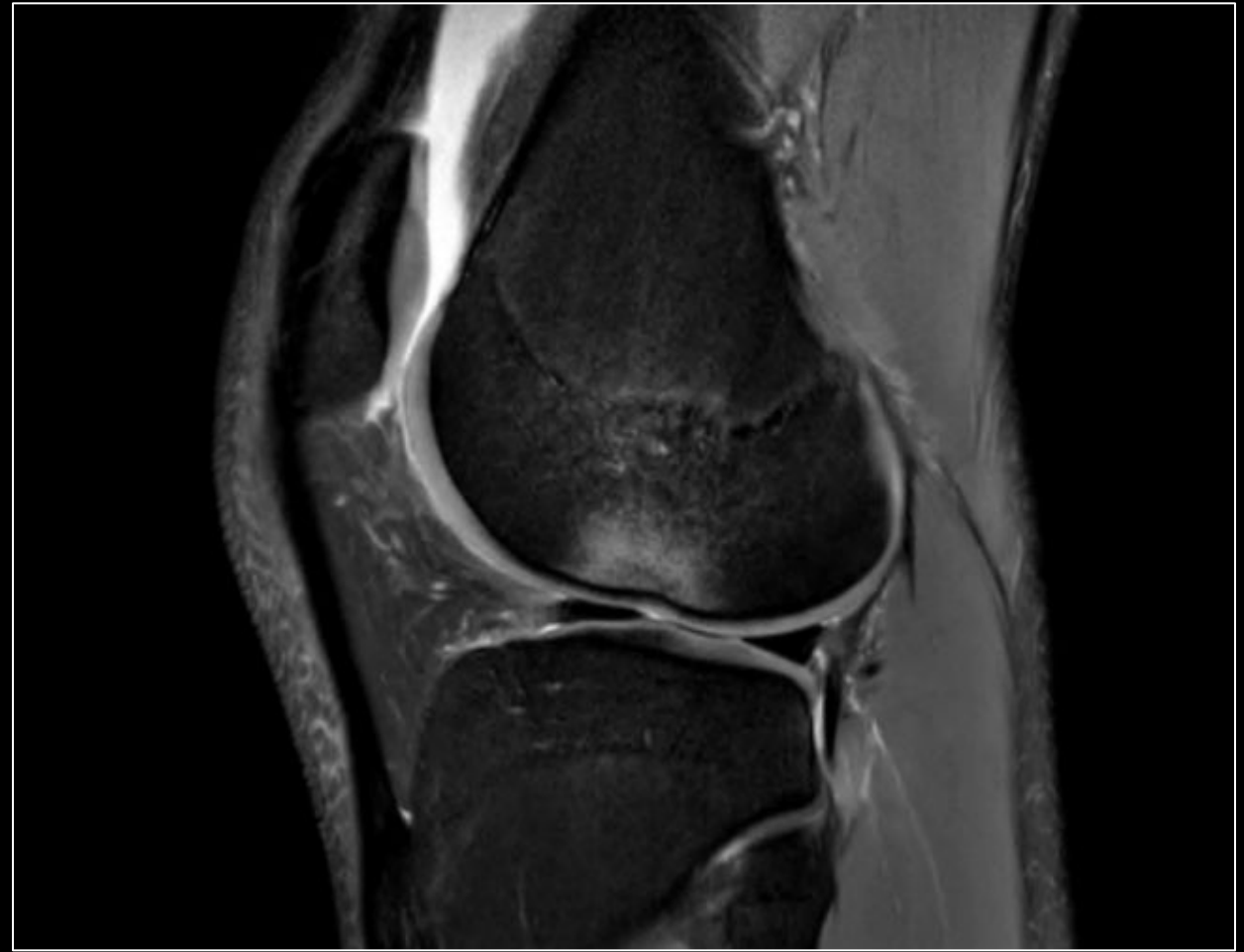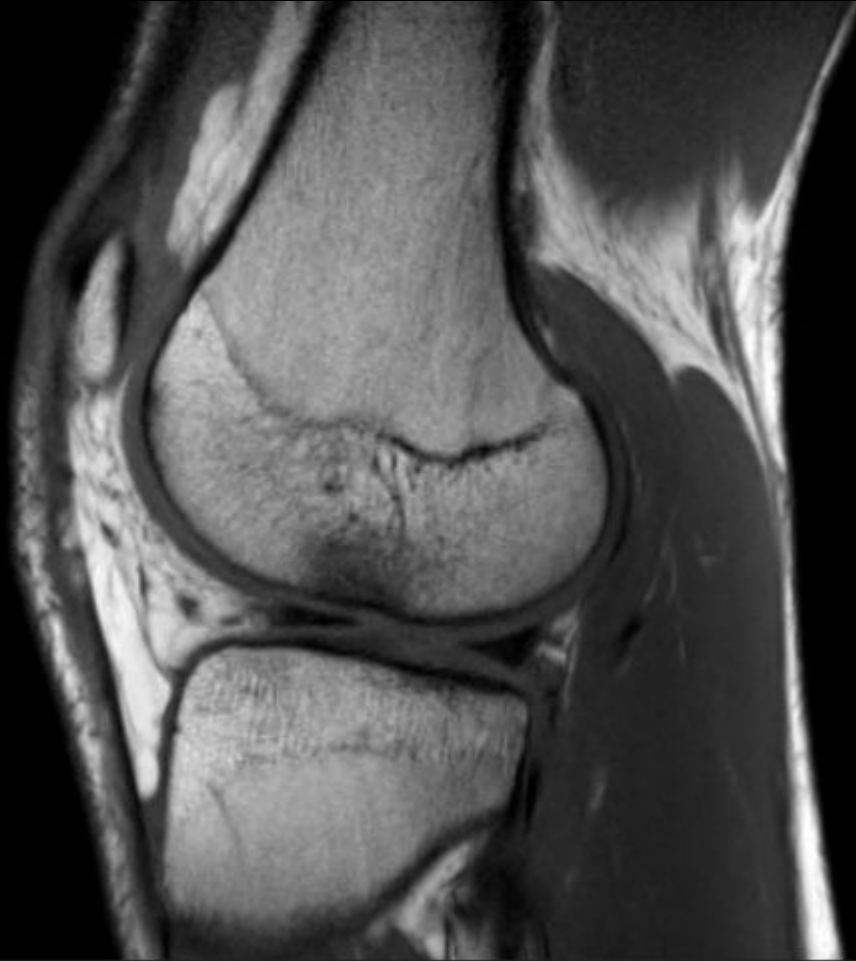Ligamentous Grading Scale

- Grade 1: The ligament has had mild damage, slightly stretch, maintains knee joint stability
- Grade 2: Partial tear: the ligament is stretched and loose, loss of stability, very rare
- Grade 3: Complete ligament tear, the ligament is split into two pieces, loss of stability

Patient Imaging



Patient Imaging



Differential Diagnosis

- Meniscus Tear
 - MCL Tear
 - LCL Tear
 - PCL Tear
 - Patellar Tendon rupture
-
- Differentiate based on imaging findings and clinical findings
 - Many of these injuries occur with an acute ACL tear

Final Diagnosis

Grade 3 ACL Tear

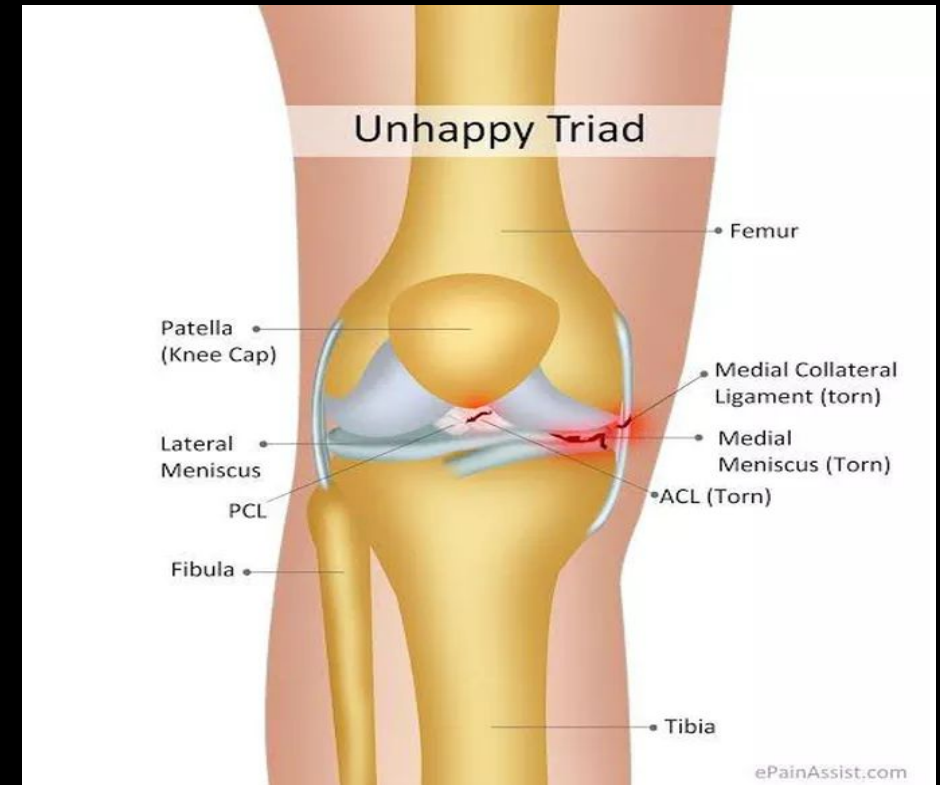
Total disruption of the ACL fibers with thickening and edema at the midportion on MRI. (+) Anterior drawer test. Given clinical picture and direct sign on imaging...

Discussion

- Patients typically present with a history of acute non-contact injury (pivoting, cutting, or jumping) or a blow to the lateral side of the knee causing excessive valgus force.
- Injury may be accompanied with a popping sensation in the knee.
- One of the most common knee injuries in the US: >200,000/year
- Greater incidence in female and younger patients participating in athletic competition

Discussion

- Other components of the knee are often also injured including the meniscus other collateral ligaments
- Must also be evaluated to determine patient management
- O'Donoghue Unhappy Triad
 - ACL Tear
 - MCL Injury
 - Medial meniscal tear

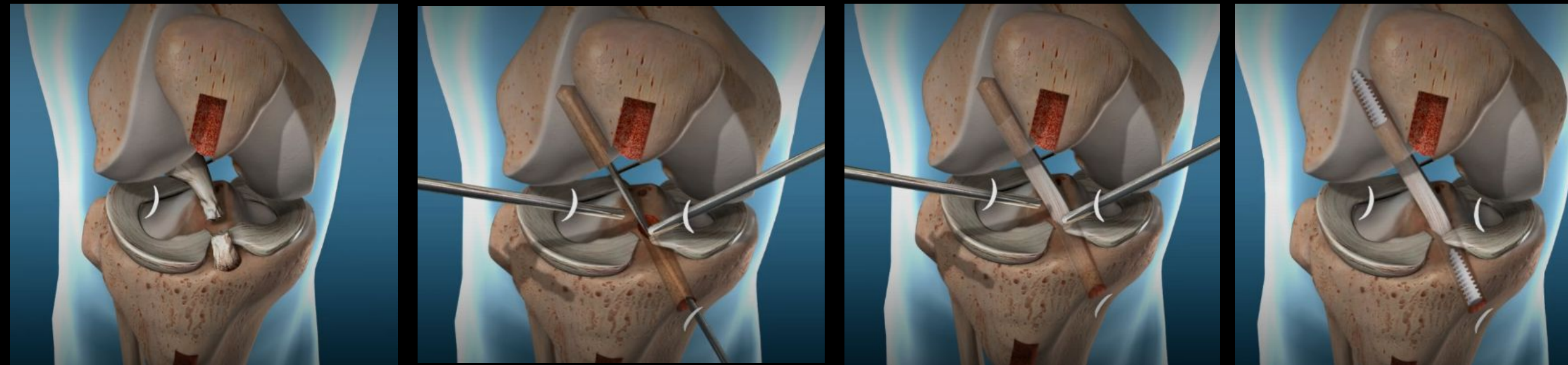


<https://medizy.com/feed/23358633>

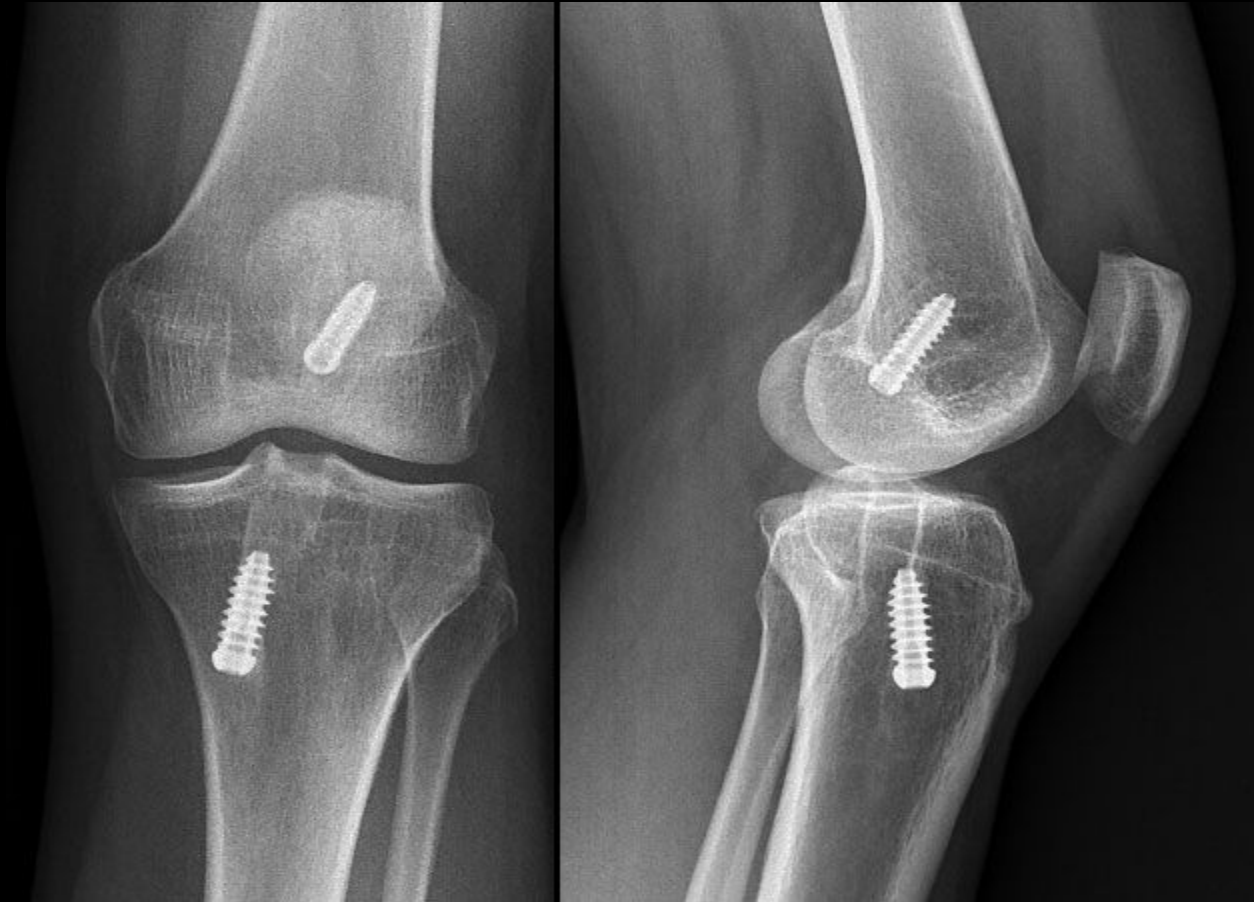
Treatment and Prognosis

- Patients can pursue nonoperative vs operative treatment
 - Nonoperative typically includes 3 months of physiotherapy and gradual return to activity with option to pursue surgery later
 - Operative management typically involves ACL reconstruction with autograft from patella, quadriceps, or hamstring tendon
- No statistical difference in final outcome related to timing of surgery
 - Patients who wish to return to activity sooner may wish to pursue operative treatment
- 40-55% of patients will return to similar or greater levels of activity
 - Return to athletics usually at least 9 months and should meet RTP protocols

Treatment (Patellar Tendon Graft)



<https://orthosports.com.au/knee/acl-reconstruction/>



<https://drrobertlaprademd.com/dr-robert-laprade-facebook-live-acl-reconstruction/>

ACR appropriateness Criteria

Variant 2: Adult or child 5 years of age or older. Fall or acute twisting trauma to the knee. One or more of the following: focal tenderness, effusion, inability to bear weight. Initial imaging.

Procedure	Appropriateness Category	Relative Radiation Level
Radiography knee	Usually Appropriate	⊕
Bone scan with SPECT or SPECT/CT knee	Usually Not Appropriate	⊕⊕⊕
CT knee with IV contrast	Usually Not Appropriate	⊕
CT knee without and with IV contrast	Usually Not Appropriate	⊕
CT knee without IV contrast	Usually Not Appropriate	⊕
MR arthrography knee	Usually Not Appropriate	0
MRA knee without and with IV contrast	Usually Not Appropriate	0
MRA knee without IV contrast	Usually Not Appropriate	0
MRI knee without and with IV contrast	Usually Not Appropriate	0
MRI knee without IV contrast	Usually Not Appropriate	0
US knee	Usually Not Appropriate	0

Variant 3: Adult or skeletally mature child. Fall or acute twisting trauma to the knee. No fracture seen on radiographs. Suspect occult fracture or internal derangement. Next study.

Procedure	Appropriateness Category	Relative Radiation Level
MRI knee without IV contrast	Usually Appropriate	0
CT knee without IV contrast	May Be Appropriate	⊕
Bone scan with SPECT or SPECT/CT knee	Usually Not Appropriate	⊕⊕⊕
CT knee with IV contrast	Usually Not Appropriate	⊕
CT knee without and with IV contrast	Usually Not Appropriate	⊕
MR arthrography knee	Usually Not Appropriate	0
MRA knee without and with IV contrast	Usually Not Appropriate	0
MRA knee without IV contrast	Usually Not Appropriate	0
MRI knee without and with IV contrast	Usually Not Appropriate	0
US knee	Usually Not Appropriate	0

Cost of Imaging

Knee xray usually cost ~\$100-\$250

Knee MRI scan cost by insurance type

Insurance type	Clinic MRI price	Hospital MRI price
High-deductible patient	\$1,200 - \$2,000	\$3,000 - \$6,000
Insured patient (25% copay)	\$300 - \$500	\$1,000 - \$2,000
Cash patient	\$225 - \$500	\$500 - \$2,000

<https://affordablesan.com/blog/knee-mri/>

Take Home Points / Teaching points

- ACL tears are common knee injuries and are most commonly caused by non-contact mechanisms
- MRI provides the greatest utility in the diagnosis of ACL tears, oblique sagittal view
- Collateral ligaments and the meniscus are also commonly injured in the setting of ACL tears
- Patients can choose between nonoperative and operative therapies

References

- Musahl, Volker, and Jon Karlsson. "Anterior cruciate ligament tear." *New England Journal of Medicine* 380.24 (2019): 2341-2348.
- Duthon, V. B., et al. "Anatomy of the anterior cruciate ligament." *Knee surgery, sports traumatology, arthroscopy* 14.3 (2006): 204-213.
- Spindler, Kurt P., and Rick W. Wright. "Anterior cruciate ligament tear." *New England Journal of Medicine* 359.20 (2008): 2135-2142.
- Ng, Wing Hung Alex, et al. "Imaging of the anterior cruciate ligament." *World journal of orthopedics* 2.8 (2011): 75.



Questions?